

sinuses and in the right ethmoidal sinuses. Oral antibiotic and antiinflammatory treatment was prescribed. The condition improved and was fully resolved a month later with no sequelae.

DISCUSSION

Sneezing is a spasmodic expiration that is accompanied by a rapid rise in intrapulmonary and intranasal pressure. During nose blowing it can reach up to 66 mm Hg. Sneezing also increases intranasal pressure, but values usually remain low (4.6 mm Hg). However, there have been reports of transient intranasal pressures reaching as much as 176 mmHg when sneezing with the mouth and nose closed.² Under normal conditions, sneezing produces no complications; nevertheless, epistaxis, headache, fractures of the stapodial foot plate and thyroid cartilage, myocardial infarction, cerebral vascular accident, transient hemiparesis, and pneumomediastinum have all been reportedly associated with sneezing. Reported ophthalmic complications include attack of acute angle-closure glaucoma³ and pneumatocele of the lacrimal sac.⁴

Orbital emphysema commonly occurs during or immediately after facial, nasal, or orbital trauma or surgical procedures, mostly after nose blowing. It is uncommon in individuals with no history of recent trauma involving orbital or periorbital structures. However, orbital emphysema has been caused by sneezing without evidence of any significant trauma.^{5,6} Our first patient had a history of nasofacial trauma, but it occurred 7 years before he presented with orbital emphysema. The second patient had a history of chronic sinusitis and had undergone nasal surgery 2 years earlier. Lamina papyracea seems to be the most common site of bony defect that allows air entry in the orbit. The prior history of trauma in our first patient and the chronic ethmoidal sinusitis in our second patient may have weakened the lamina papyracea and, therefore, the increase of pressure produced by sneezing may have disrupted the orbital wall with resultant passage of air to the orbital space.

In most cases, careful observation and the recommendation to avoid nose blowing are the only treatment necessary for orbital emphysema. According to the severity of the condition, the use of nasal decongestants, antibiotics, air drainage, direct decompression, and steroids have been used for treatment. Our patients were prescribed decongestants, antibiotics, non-steroidal anti-inflammatory drugs, and were given general recommendations such as the avoidance of nose blowing.

Our cases show that the risk of emphysema after sneezing should be considered in patients with a history of surgery or past trauma involving orbital or periorbital

structures. Other reported cases indicate that this is an incidental and benign finding with spontaneous resolution within a few days or weeks.^{5,6}

REFERENCES

1. Leung AKC, Robson LM. Sneezing. *J Otolaryngol* 1994;23:125-9.
2. Gwaltney JM Jr., Hendley JO, Phillips CD, et al. Nose blowing propels nasal fluid into the paranasal sinuses. *Clin Infect Dis* 2000;30:387-91.
3. Sharir M, Huntington AC, Nardin GF, Zimmerman TJ. Sneezing as a cause of acute angle-closure glaucoma. *Ann Ophthalmol* 1992;24:214-5.
4. Rochels R, Bleier R, Nover A. Compression pneumatocele of the lacrimal sac. *Klin Monatsbl Augenheilk* 1989;195:174-6.
5. Mohan B, Singh KP. Bilateral subcutaneous emphysema of the orbits following nose blowing. *J Laryngol Otol* 2001;115:319-20.
6. Kaplan K, Whinchell GD. Orbital emphysema from nose blowing. *N Engl J Med* 1968;278:1234.

Bilateral Progressive Enophthalmos as the Presenting Sign of Metastatic Breast Carcinoma

Allan C. P. Gonçalves, M.D.,
Frederico C. Moura, M.D., and
Mário L. R. Monteiro, MD, Ph.D.

Abstract: A 51-year-old woman, without systemic symptoms, complained of slowly progressive receding eyes. She had severe bilateral enophthalmos and markedly restricted extraocular movements in all fields of gaze. Computed tomography showed an infiltrative homogenous mass filling both orbits. Gynecologic and systemic investigation revealed bilateral lobular breast carcinoma, without metastasis to other organs. She was started on chemotherapy and 2 years after the diagnosis remains in good general health, despite persistence of severe enophthalmos. This case serves to emphasize that bilateral progressive enophthalmos may be the presenting sign of metastatic breast carcinoma even when local symptoms in the breast are absent. Clinicians should be aware of this sign to establish an early diagnosis and treatment.

Progressive enophthalmos in the absence of previous trauma, surgery, or inflammatory process is an uncommon condition. When associated with other char-

Department of Ophthalmology, Hospital das Clínicas of the University of São Paulo Medical School, São Paulo, Brazil.

Accepted December 6, 2004.

Address all correspondences and reprint requests to Dr. Mário L. R. Monteiro, Av. Angélica 1757 conj. 61, 01227-200, São Paulo, SP, Brazil; E-mail: mlrmonteiro@terra.com.br

DOI: 10.1097/01.iop.0000167786.00697.0b

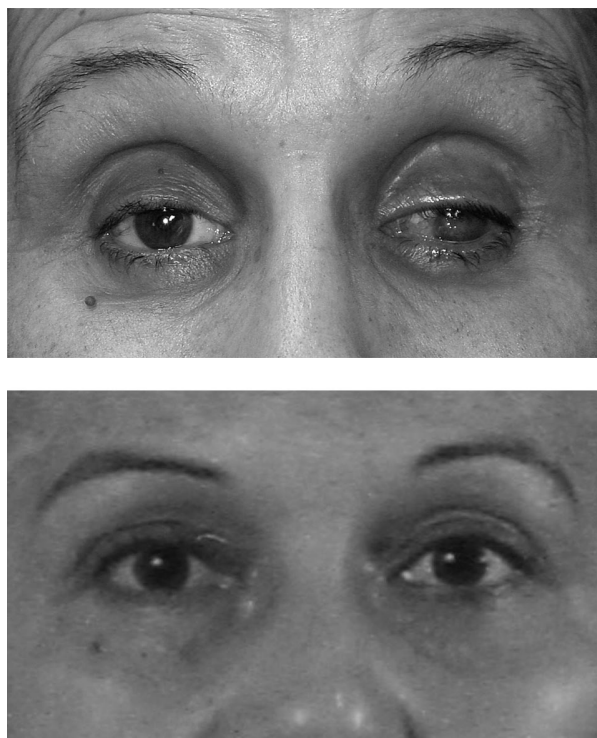


FIG. 1. Above, patient appearance at the time of presentation with severe bilateral enophthalmos. Below, appearance from an old photograph prior to the initial of symptoms.

acteristic signs or symptoms it has been described in patients with maxillary mucoceles, chronic sinusitis, or neurofibromatosis.^{1,2} Bilateral progressive and isolated enophthalmos is an even more uncommon condition with very few cases described in the literature.¹⁻³

Herein we report the case of one patient who presented to the ophthalmologist complaining of bilateral progressive enophthalmos over several months and who subsequently was found to have presumed bilateral orbital metastasis from a previously undiagnosed breast carcinoma. This case serves to emphasize the importance of recognizing this uncommon clinical sign.

CASE REPORT

A 51-year-old woman complained of progressively receding eyes over the previous 14 months. She also complained of dryness and irritation in both eyes, especially in the left eye. There was no previous clinical diseases and she had no systemic complaints. The patient was previously examined by an ophthalmologist who

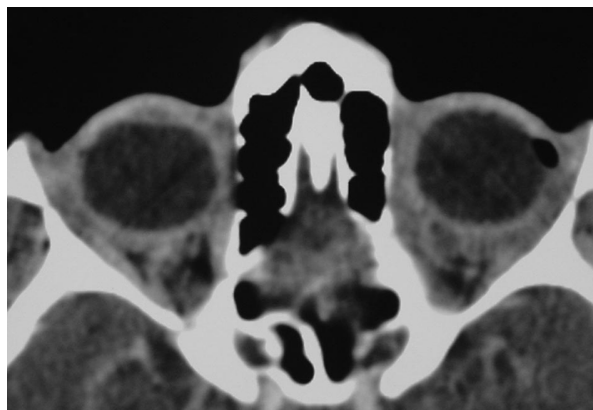


FIG. 2. Computerized tomography scan showing marked bilateral enophthalmos and infiltrating homogeneous mass filling both orbits.

diagnosed mild senile ptosis and prescribed reading glasses and lubricating eye drops.

On examination her best corrected visual acuity was 20/20 OD and 20/40 OS. There was bilateral severe enophthalmos with Hertel exophthalmometry readings of 11 mm OD and 10 mm OS (Fig. 1). There were deep supratarsal folds and the eyelids were poorly apposed to the globes with narrowing of the palpebral fissure OU. She was orthophoric in primary position but the ocular motility in both eyes was markedly limited in all fields of gaze. Slit lamp examination showed interpalpebral punctate epitheliopathy in both eyes and superficial corneal ulcer OS. CT showed marked bilateral enophthalmos and infiltrating homogenous mass filling both orbits in axial and coronal scans (Fig. 2). Orbital metastasis was suspected and a general clinical and gynecological investigation revealed bilateral breast nodules. Bilateral breast biopsy revealed lobular carcinoma on both sides. She was started on chemotherapy with cyclophosphamide and adriamycin with good response of the breast lesions. Two years after the diagnosis she remains in good general health. She underwent bilateral canthoplasty and intensive lubricating eye drops for treatment of her epitheliopathy and corneal ulcerations. Bilateral enophthalmos remains unchanged.

DISCUSSION

Enophthalmos is an important clinical sign in orbital diseases and can be due to an imbalance of the orbital volume and its contents. Such imbalance can be caused by one of three mechanisms: bony structural abnormality, orbital fat atrophy, or "traction" (cicatrization) of the

orbital tissues. Examples of structural abnormalities causing enophthalmos include congenital orbital asymmetry, trauma, maxillary hypoplasia, chronic sinusitis with orbital floor destruction, congenital absence of the sphenoid wing as in neurofibromatosis, and microphthalmos. Orbital fat atrophy may be caused by scleroderma, postirradiation effect, following orbital hemorrhage, orbital varix, systemic or drug induced lipodystrophy, or repeated self-inflicted orbital pressure as in schizophrenia. Traction or cicatrization mechanism may be caused by cicatrizing metastatic tumors, postinflammatory cicatrization of muscles, postsurgical extraocular muscle shortening and transiently following succinylcholine injection.^{1,2}

Breast carcinoma is the most common metastatic tumor of the ocular structures.^{4,5} In a review of 28 cases of carcinoma metastatic to the orbit, Font and Ferry⁵ found that 8 cases had breast carcinoma. Other sites of primary tumors included: lung (4 cases); genitourinary tract (4 cases); pancreas (1 case); ileum (1 case); and in 10 cases, the sites were undetermined. The most common signs and symptoms caused by orbital metastasis in this series included exophthalmos (75%), pain (29%), decreased vision (29%), periorbital swelling (25%), a visible mass (21%), ophthalmoplegia, and diplopia (18%). Unilateral enophthalmos was present in two patients with metastatic breast carcinoma.⁵

Breast carcinoma metastatic to the orbit tends to localize to orbital fat and muscle tissue and usually occurs in the fifth decade of life. Most tumors have an extended time course and the primary tumor is usually diagnosed long before the patient presents to the ophthalmologist. The average interval from primary diagnosis to orbital metastasis varies from 4 to 6 years.⁴ In a small percentage of patients orbital metastasis may be the presenting sign of breast carcinoma. When orbital metastasis precedes the diagnosis of the primary breast carcinoma, diagnostic confusion is common and close attention to the clinical signs of orbital metastasis is important. It typically presents as a firm infiltration of tumor cells in the orbit with proptosis and restricted extraocular movements, ptosis, and in some cases, enophthalmos.⁴

Enophthalmos is an important and well-documented clinical sign of breast carcinoma metastasis.^{2,3,6-8} When observed in a patient with orbital metastasis, such a sign is strongly suggestive of breast carcinoma. The mechanism of enophthalmos in breast carcinoma is probably by contraction of fibroblasts in the diffuse scirrhous orbital tumor leading to posterior traction and tethering of the globe.⁸ Reifler⁹ reviewed 25 cases from the literature of orbital metastasis presenting with enophthalmos and found that 19 (76%) were caused by breast carcinoma. In

the remaining 6 cases (24%), the carcinoma originated in the abdomen. Three cases involved carcinomas arising from the stomach; the other primary sites included one from the colon, one from the pancreas, and one that could not be further specified.⁹ In a large review of 207 cases of metastatic orbital tumors drawn from the literature, Goldberg et al.⁸ found 22 with unilateral enophthalmos, 18 of which were caused by breast carcinoma. The authors commented that gastrointestinal (2 cases) and lung (1 case) are among the metastatic tumors, including prostate, which occasionally present with enophthalmos.⁸ It is therefore important to keep in mind that tumors other than breast carcinoma can rarely cause enophthalmos and should also be included in the differential diagnosis.

In most reports of metastatic breast carcinoma, enophthalmos has been described as unilateral.^{2,5-9} Slowly progressive bilateral enophthalmos from metastatic breast carcinoma has only been reported in one paper by Kuzma and Goodman in a patient who had an established diagnosis of breast carcinoma.³ Therefore, our case is important because it highlights the occurrence of progressive, long-standing enophthalmos as the only clinical sign of metastatic breast carcinoma. It also illustrates the importance of a careful differential diagnosis of enophthalmos that takes in consideration the possibility of a metastatic tumor. In such cases, a precocious diagnosis may hasten treatment and therefore improve survival. While we recognize that the orbital diagnosis in this case was presumptive—in the absence of a direct orbital biopsy—we believe that the evidence was overwhelming for bilateral orbital metastases.

REFERENCES

1. Meyer DR, Nerad JA, Newman NJ, et al. Bilateral enophthalmos associated with hydrocephalus and ventriculoperitoneal shunting. *Arch Ophthalmol* 1996;114:1206-9.
2. Cline RA, Rootman J. Enophthalmos: a clinical review. *Ophthalmology* 1984;91:229-37.
3. Kuzma BK, Goodman JM. Slowly progressive bilateral enophthalmos from metastatic breast carcinoma. *Surg Neurol* 1998;50:600-2.
4. Reeves D, Levine MR, Lash R. Nonpalpable breast carcinoma presenting as orbital infiltration: Case presentation and literature review. *Ophthalm Plast Reconstr Surg* 2002;18:84-8.
5. Font RL, Ferry AP. Carcinoma metastatic to the eye and orbit III. A clinicopathologic study of 28 cases metastatic to the orbit. *Cancer* 1976;38:1326-35.
6. Stefanyszyn MA, DeVita EG, Flanagan JC. Breast carcinoma metastatic to the orbit. *Ophthalm Plast Reconstr Surg* 1987;3:43-7.
7. Glazer LC, Harris GJ, Simons KB. Orbital metastasis as the presenting sign of adenocarcinoma of the breast. *Ophthalm Plast Reconstr Surg* 1991;7:252-5.
8. Goldberg RA, Rootman J, Cline RA. Tumors metastatic to the orbit: a changing picture. *Surv Ophthalmol* 1990;35:1-24.
9. Reifler DM. Orbital metastasis with enophthalmos: a review of the literature. *Henry Ford Hosp Med J* 1985;33:171-9.